# Fix It or Shave It? Meniscus Repair


LECOM Summer CME 2019

Joshua A. Tuck, D.O., M.S., FAOAO
LECOM Health
Orthopedic and Sports Medicine

# Disclosures

The presenter has no relevant financial relationships to be discussed, directly or indirectly, referred to or illustrated with or without recognition within this presentation.

# Goals and Objectives

**Goals:** Participants will improve their understanding of meniscus tear pathology and indications for operative vs. non-operative management, to include meniscal repair vs. debridement.

**Objectives:** Participants will be expected to:

- Discuss the diagnosis of meniscus tear.
- Describe the anatomy of the meniscus, as well as the various types of meniscus tears.
- Discuss the decision-making process for meniscus debridement vs. repair.

# Meniscus Anatomy

- Medial meniscus
  - More C-shaped
  - 9-10mm wide
  - 3-5 mm thick
  - More intimately in contact with the capsule
- Lateral Meniscus
  - More circular
  - 10-12 mm wide
  - 4-5 mm thick
  - More mobile d/t less capsular attachment

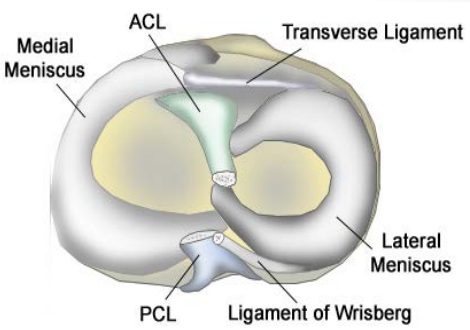

# Meniscus Anatomy

- Cross section
  - Triangular shaped
  - 3 zones
    - Red/Red
    - Red/white
    - White/white
  - Blood supply
    - Medial geniculate arteries
    - Lateral geniculate arteries

Must Keep in mind when deciding on repair vs. debridement!

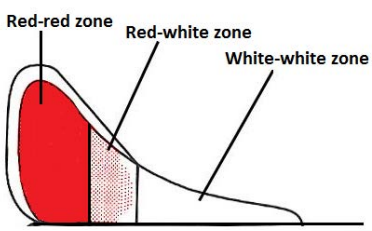



# Meniscus Composition

- Fibroelastic cartilage
  - 70% collagen (Dry weight)
    - 90% type I
  - 70% water (wet weight)
  - Fibers
    - Radial
    - Longitudinal / circumferential
      - Dissipate hoop stresses

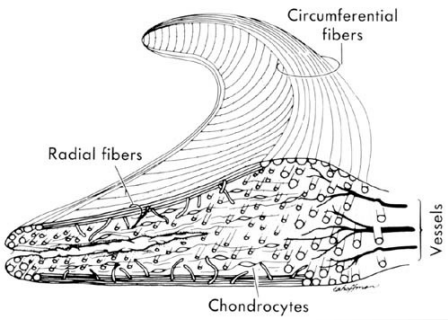

# Diagnosis

- History of twisting type injury
  - Mechanical symptoms of locking, popping, giving out
  - Insidious
- Physical exam
  - Joint line tenderness
  - McMurray
  - Thessaly

# Diagnosis

- Imaging
  - Plain film imaging
    - Usually normal
  - MRI
    - Highly sensitive but high false positive rate
    - Signal intensity increase extending to sup/inferior edge "grade III"

# Types of Tears

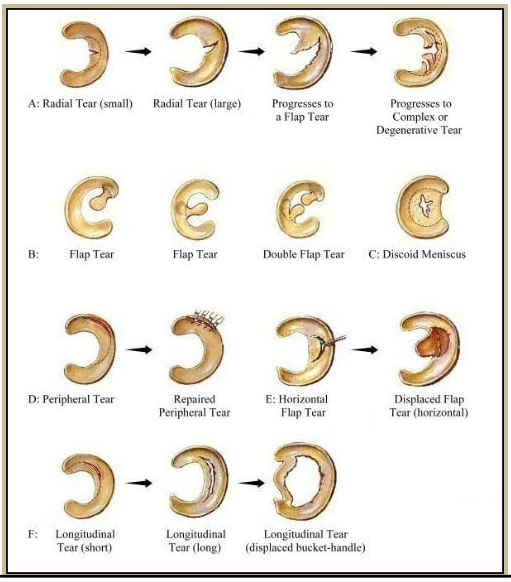


# Repair vs Partial Meniscectomy

- Classic indications for repair
  - Young patient (35?)
  - Peripheral tear (red-red or red-white zone)
  - Vertical or longitudinal tears
  - > 1cm in length
- Can we step outside these indications and still expect good results?

# History

- 1883 first meniscus repair - Sir Thomas Annandale
- 1889 first meniscectomy - Sir Thomas Annandale
- 1908 case series by Dr. Katzenstein

"Repair superior to excision unless meniscus is degenerative"

- 1948 clinical effects of complete excision – Sir Thomas Fairbank
- 1962 first arthroscopic meniscectomy – Masaki Watanabe
- 1969 first arthroscopic meniscus repair – Hiroshi Ikeuchi

# What about today?

## Surgical Trends in the Treatment of Meniscus Tears:

## Analysis of Data from the American Board of Orthopaedic Surgery

## Certification Examination Database

- Query of the American Board of Orthopaedic Surgery (ABOS) database was used to identify patients from 2004-2012 who underwent meniscal repair and partial meniscectomy
- Showed increase rate of meniscus repair
- Decrease rate of partial meniscectomy

Benjamin Parker, MD, Shepard R. Hurwitz, MD, Jeffrey T. Spang, MD, Robert A. Creighton, MD, Ganesh V. Kamath, MD. Surgical Trends in Treatment of Meniscus Tears: Analysis of Data from the American Board of Orthopaedic Surgery Certification Examination Database. Orthopaedic Journal of Sports Medicine . 2015;3

# Advantages of Meniscus Repair

- **Multiple studies demonstrate increased degenerative changes after meniscectomy.**

At 21 years after open meniscectomy (compared to matched controls)

Roos H, et al. Knee osteoarthritis after meniscectomy: prevalence of radiographic changes after 21 years, compared with matched controls. *Arthritis Rheum. 1998*

- Advanced radiographic changes: 48%
- Relative risk for radiographic DJD = 14.0

- **But successful repair seems to be protective / preventive.**

(Stein et al, AJSM, 2010)

- 81 arthroscopic MMR
- At 8.8 years = no arthritis detectable in 80.8% repaired, compared with 40% after meniscectomy.
- Returned to baseline sports level – 96.2% after repair vs. 50% after meniscectomy.

Stein T, et al. Long-term outcome after arthroscopic meniscal repair versus arthroscopic partial meniscectomy for traumatic meniscal tears. *Am J Sports Med*. 2010

## Factors Affecting the Outcomes of Arthroscopically Repaired Traumatic Longitudinal Medial Meniscal Tears

- 80 patients with longitudinal or bucket-handle medial meniscus tears
- Pt age 18-49 (divided two groups <30, >30)
- Single surgeon
  - All inside or hybrid (all inside with inside out)
  - 2 outside-in in repairs
- f/u 34-85 months
- 90% (72)
  - No complaints at final f/u
- 3 factors predicted failure with significant statistics
  - Smoking
  - >8 weeks from time of injury
  - Red-white zone more likely than red-red zone tears***
- No difference in age groups*** (range 18-49)

- Erdal Uzun, MD, , Abdulhamit Misir, MD, Turan Bilge Kizkapan, MD, Mustafa Ozcamdalli, MD, Soner Akkurt, MD, Ahmet Guney, MD. Factors Affecting the Outcomes of Arthroscopically Repaired Traumatic Vertical Longitudinal Medial Meniscal Tears . Orthopaedic Journal of Sports Medicine . 2017;5:1-7.

## Results of Arthroscopic Meniscal Repair

- 62 meniscus tears in 58 patients
- Average age 31 years old (15-58)
- Average f/u 50 months (6-120)
- All inside, inside-out, outside-in, and combinations used
- Success rate of 93.5%
  - Failure occurred in 4 patients (1 ACL recon, 3 all-suture repairs)

Orlowski, M. B., MD, Arroquy, D., MD, Bisso, M. C., MD, & Vilaseca, T., MD. (2017). Results of Arthroscopic Meniscal Repair. *Orthopaedic Journal of Sports Medicine , 5.* doi:10.1177/2325967117S00010

## Inside-out Meniscal Repair

# Inside-out repair

- Advantages
  - "Gold Standard"
  - Greater flexibility for complex tears
  - Use multiple vertical mattress sutures
    - Number depends on size of tear
  - Good for posterior horn

# Inside-out repair

- Disadvantages
  - Risk of N-V injury, (politeal A/V, peroneal nerve)
  - Requires assistance
  - Possibly more time consuming


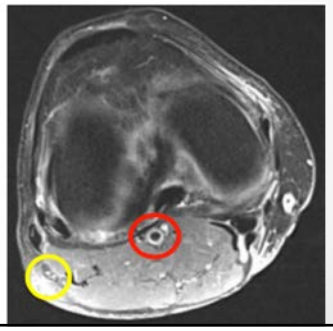

# Outside-in repair

- Great for anterior horn tears
- Lassos or spinal needle to pass / shuttle suture
- Small incision down to capsule
  - Knot tied over the capsule
- Must take care not to have soft tissue bridge
  - Cannula can be helpful

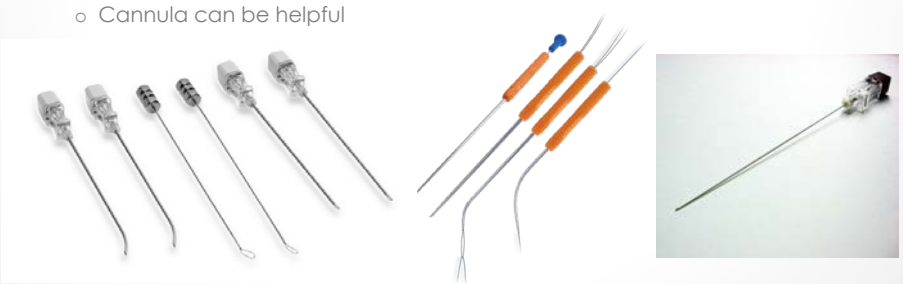

# Outside-in repair

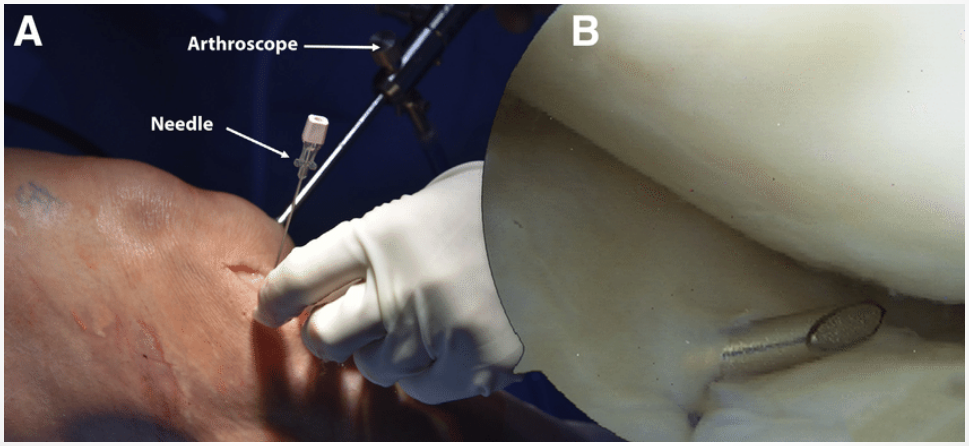


# All-inside repair

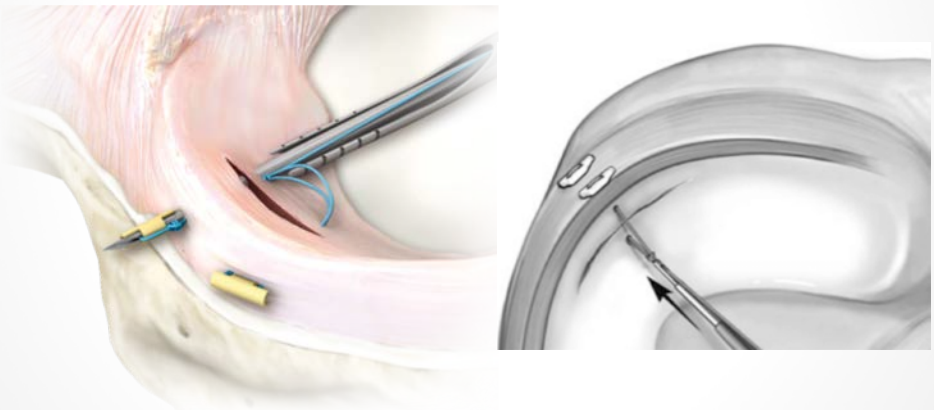

# All-inside repair: Choose your weapon


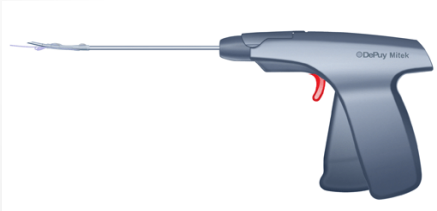


# Other meniscus repair tools (all-suture repairs)

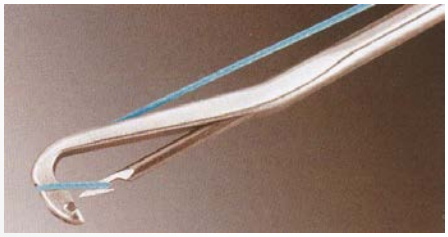

# Hybrid Repairs

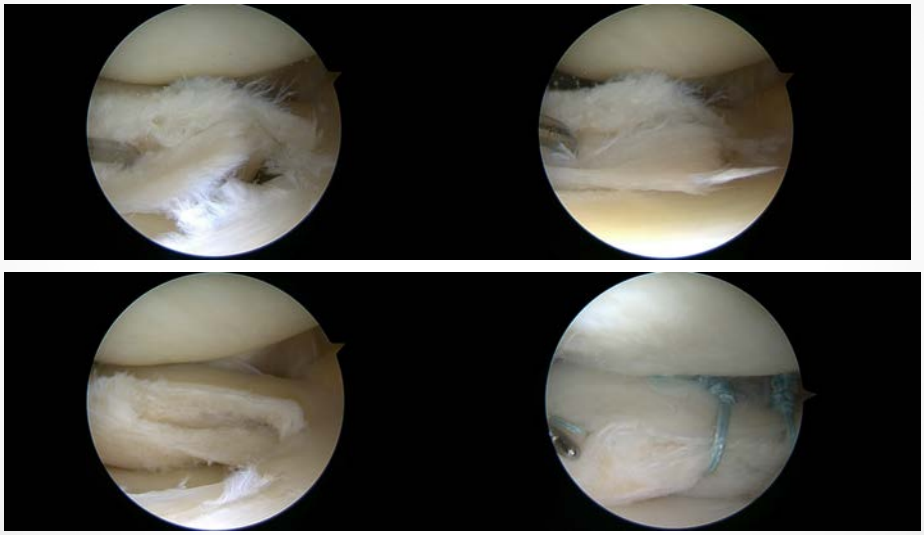

# Outside-in, inside-out and all-inside repairs

**Modern "2nd, 3rd, 4th generation" All-inside repairs have shown excellent results.**

**Bioabsorbable / rigid implants (darts, arrows, screws) mixed studies:**
- Decreased load to failure / pull-out strength
- I mplant migration / failure to resorb / synovitis
- 38% failure at 4.7 years. (Biofix Arrows - Gifstad T, et al. - *AJSM* 2007)

**All-suture inside devices appear superior to rigid devices:** (Biofix arrows vs. FasT-Fix: Kise NJ, et al. *Knee Surg Sports Traumatal Arthrosc* 2015
- 43% failure with Biofix
- 12% failure with FasT-Fix.
- RR of re-operation = 3.6 times higher for Biofix.



**Modern suture-based all-inside devices have shown comparable results to more traditional techniques.**

These are all options for longitudinal / vertical tear patterns.

What about other tear patterns?

What about radial tears in the red or red-white zones?

New Suture Method for Radial Tears of the Meniscus

Biomechanical Analysis of Cross-Suture and Double

Horizontal Suture Techniques Using Cyclic Load Testing

- 40 fresh human lateral menisci
  - Tested within 24 hours of harvest
- 2 suture groups, 2.0 prolene
  - Group A – cross-suture group
  - Group B – standard double horizontal
- Cyclically loaded and elongated

Hirokazu Matsubara,* MD, Ken Okazaki,*y MD, PhD, Toshiaki Izawa,* MD, Yasutaka Tashiro,* MD, PhD, Shuichi Matsuda,* MD, PhD, Takuya Nishimura,z PhD, Yoshitaka Nakanishi,z PhD, Hideya Kawamura,§ MD, PhD, and Yukihide Iwamoto,* MD, PhD. ew Suture Method for Radial Tears of the Meniscus Biomechanical Analysis of Cross-Suture and Double Horizontal Suture Techniques Using Cyclic Load Testing. The American Journal of Sports Medicine. 2012;40(2):414-418.

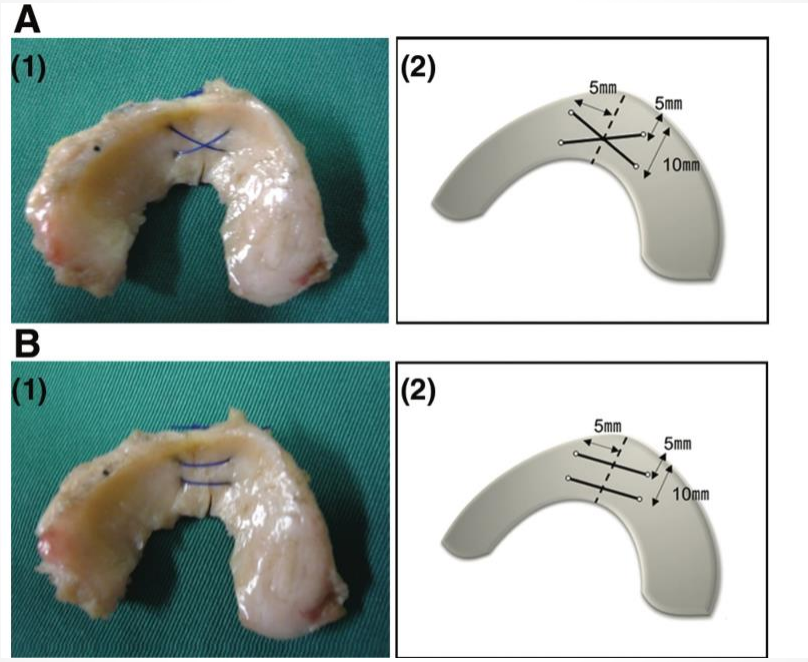
A
(1)
(2)
5mm
5mm
10mm
B
(1)
(2)
5mm
5mm
10mm

## New Suture Method for Radial Tears of the Meniscus

## Biomechanical Analysis of Cross-Suture and Double Horizontal Suture Techniques Using Cyclic Load Testing

- **Cross suture technique**
  - Higher load to failure
  - Greater stiffness
  - Lower displacement
- **Failure**
  - In both groups, tissue failed more often than suture

TABLE 1
Ultimate Failure Load, Stiffness, and Displacement of Meniscal Repair Devices After 500 Cyclic Loading Between 5 and 30 N

| | Ultimate Failure Load, N | Stiffness, N/mm | Displacement 1,[a] mm | Displacement 2,[b] mm |
|---|---|---|---|---|
| Cross-suture | 78.96 ± 19.27 | 8.01 ± 1.54 | 5.74 ± 1.84 | 10.31 ± 3.56 |
| Double horizontal suture | 68.16 ± 12.92 | 6.46 ± 1.12 | 8.56 ± 2.39 | 10.77 ± 2.31 |

[a]Displacement 1: displacement after cyclic load testing.
[b]Displacement 2: displacement after load-to-failure test.

Hirokazu Matsubara,* MD, Ken Okazaki,*y MD, PhD, Toshiaki Izawa,* MD, Yasutaka Tashiro,* MD, PhD, Shuichi Matsuda,* MD, PhD, Takuya Nishimura,z PhD, Yoshitaka Nakanishi,z PhD, Hideya Kawamura,§ MD, PhD, and Yukihide Iwamoto,* MD, PhD. ew Suture Method for Radial Tears of the Meniscus Biomechanical Analysis of Cross-Suture and Double Horizontal Suture Techniques Using Cyclic Load Testing. The American Journal of Sports Medicine. 2012;40(2):414-418.

## Repair of a complete radial tear in the midbody of the medial meniscus using a novel crisscross suture transtibial tunnel surgical technique: a case report.

- Case study depicting new complete radial tear fixation technique
  - 29-year-old male
  - Mountain biking injury
  - + MRI
- Uses 2 tibial bone tunnels to secure meniscus
- Horizontal mattress sutures to approximate torn edges


- James, E. W., Laprade, C. M., Feagin, J. A., & Laprade, R. F. (2014). Repair of a complete radial tear in the midbody of the medial meniscus using a novel crisscross suture transtibial tunnel surgical technique: a case report. *Knee Surgery, Sports Traumatology, Arthroscopy*, 23(9), 2750-2755. doi:10.1007/s00167-014-3089-z

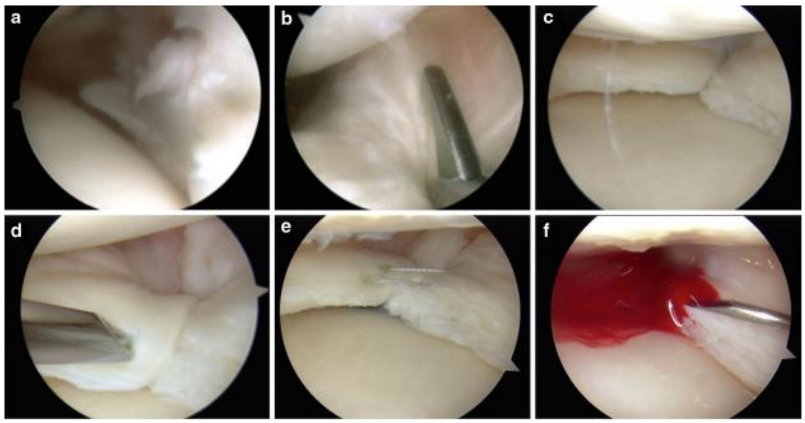


**Fig. 2** Arthroscopic images showing the progression of the surgical repair (*right knee*). **a** A complete radial tear in the midbody of the medial meniscus; **b** freeing the meniscus from its scarred in position along the joint capsule; **c** securing the anterior and posterior horns; **d** reapproximating the torn margins; **e** two horizontal mattress sutures in the radial tear; **f** PRP and BMAC adjuvant

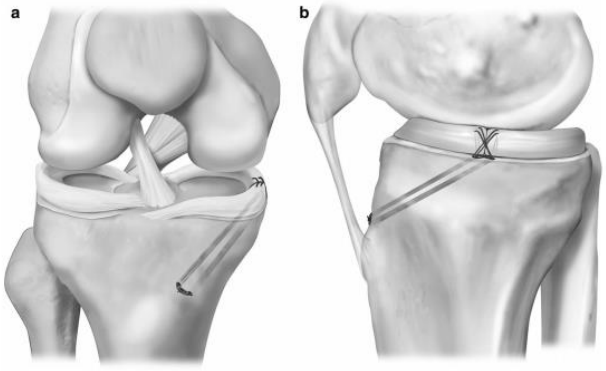


Springer

## Repair of a complete radial tear in the midbody of the medial meniscus using a novel crisscross suture transtibial tunnel surgical technique: a case report.

RESULTS:

- No pain, loss of ROM or mechanical symptoms, returned to sport at 12 months without issue.
- Complete healing on second look arthroscopy at 6 months noted.

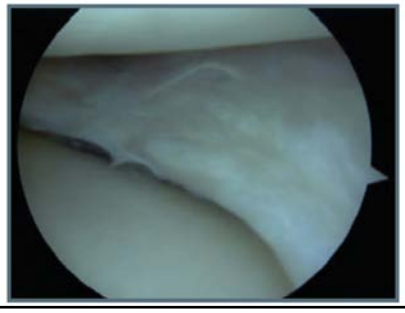

# Meniscal Root Tears

- Root tears are another animal
  - Destabilize the entire meniscus
  - More difficult to reach with standard arthroscopy tools
  - Require more fixation

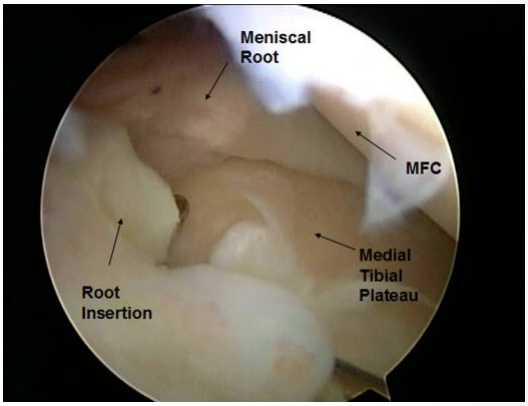

## Biomechanical Comparison of Arthroscopic Repair Constructs for Meniscal Root Tears

- 40 cadaveric meniscal roots from 21 knees
- 5 medial and 5 lateral roots per suture group
  - 2 simple sutures (2SS),
  - 1 inverted mattress suture(1MS)
  - 1 double-locking loop suture (1DLS)
  - 2 doublelocking loop sutures (2DLS)
- Sutures placed arthroscopically
- Menisci were then excised for testing

Anz AW, et al. Biomechanical Comparison of Arthroscopic Repair Constructs for Meniscal Root Tears. *Am J Sports Med.* 2014;42(11):2699-2706.

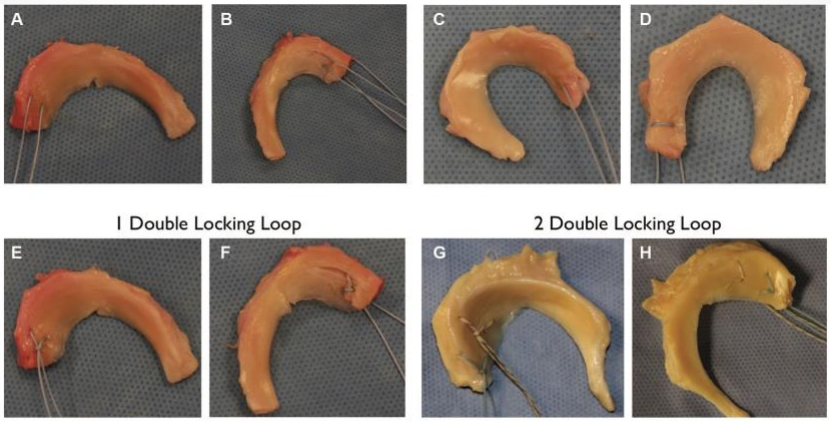


**Figure 1.** Meniscal repair constructs: (A, C, E, G) femoral views and (B, D, F, H) tibial views. (A, B) 2 simple sutures, (C, D) 1 inverted mattress suture, (E, F) 1 double-locking loop suture, and (G, H) 2 double-locking loop sutures.

Anz AW, et al. Biomechanical Comparison of Arthroscopic Repair Constructs for Meniscal Root Tears. *Am J Sports Med.* 2014;42(11):2699-2706.

## Biomechanical Comparison of Arthroscopic Repair Constructs for Meniscal Root Tears

- 2 Double Locking Suture – Highest load to failure
- 1 Mattress Suture – lowest load to failure

TABLE 1
Results of Uniaxial Tension Testing[a]

| Construct | Failure Load, N | Preconditioning Stiffness, N/mm | Postconditioning Stiffness, N/mm | Repair Time, min |
|---|---|---|---|---|
| 2 double-locking loop sutures | 368 ± 76 (468-204) | 20.8 ± 3.1 (28.1-16.9) | 31.1 ± 5.0 (39.8-22.9) | 5.4 ± 0.6 (6.5-4.8) |
| 1 double-locking loop suture | 186 ± 43 (251-132) | 9.7 ± 2.1 (14.2-7.7) | 21.9 ± 6.1 (30.6-13.6) | 4.7 ± 2.0 (2.3-8.3) |
| 2 simple sutures | 137 ± 49 (258-68) | 20.6 ± 4.1 (28.5-13.8) | 31.5 ± 7.2 (44.4-21.8) | 1.8 ± 0.9 (3.3-1.0) |
| 1 inverted mattress suture | 126 ± 44 (192-69) | 11.7 ± 4.5 (18.8-4.0) | 26.8 ± 5.8 (34.9-19.2) | 2.4 ± 1.9 (3.2-0.8) |

[a]Values are presented as mean ± SD (range).

Anz AW, et al. Biomechanical Comparison of Arthroscopic Repair Constructs for Meniscal Root Tears. *Am J Sports Med.* 2014;42(11):2699-2706.

What are some techniques for meniscal root tears?

## All-Inside Repair for a Root Tear of the Medial Meniscus Using a Suture Anchor

- 13 medial meniscus root tears
- Repaired with suture anchor
- Portals
  - Anteromedial
  - Anterolateral
  - High posteromedial **(4 cm proximal to jt line, posterior to MFC**)
- Metal anchor with FiberWire (Arthrex, Naples, FL)
- Suture shuttling with curved suture hook / PDS – arthroscopic knots
- 30.8 mos follow-up
- Level IV evidence - case series

Jung YH, et al. All-Inside Repair for a Root Tear of the Medial Meniscus Using a Suture Anchor. *Am J Sports Med.* 2012

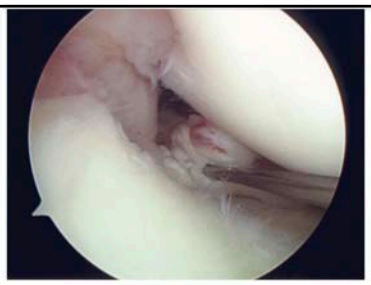

**Figure 2.** Arthroscopic view of a posterior root tear of the medial meniscus.

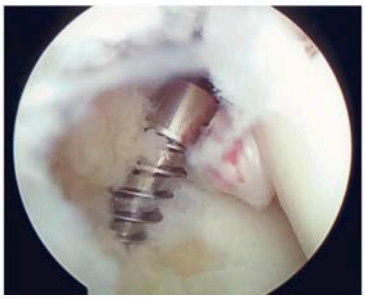

**Figure 4.** Postoperative (A) anteroposterior and (B) latera radiographs after suture anchor fixation.

articular cartilage of the lateral tibial plateau and the out

Jung YH, et al. All-Inside Repair for a Root Tear of the Medial Meniscus Using a Suture Anchor. *Am J Sports Med.* 2012

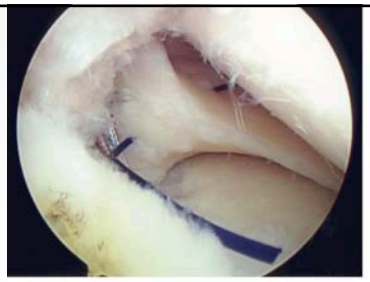

igure 5. A PDS (Ethicon) used as a suture shuttle was pen-trated from the superior to inferior surface of the medial eniscus.

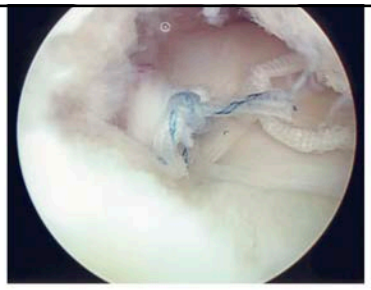

**Figure 7.** A sliding knot was made securely for each Fiber-Wire (Arthrex), and a posterior root tear of the medial menis-cus was repaired by the all-inside repair technique.

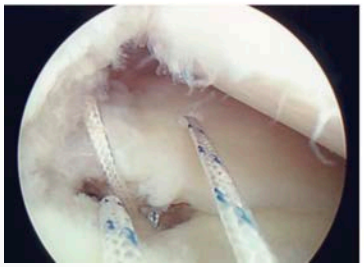

Jung YH, et al. All-Inside Repair for a Root Tear of the Medial Meniscus Using a Suture Anchor. *Am J Sports Med.* 2012

## All-Inside Repair for a Root Tear of the Medial Meniscus Using a Suture Anchor

- Improvement
  - Tegner scores
    - Improved from 1.9 to 3.9
  - Lysholm score
    - Improved from 69.1 to 90.3.
  - All post operative McMurray exams were negative
- 10 of 13 patients had post op MRI
  - 5 patients showed complete healing
  - 4 patients showed partial healing
  - 1 patient showed no healing

**All had symptomatic improvement in repairs, although all did not demonstrate full healing on MRI.**

Jung YH, et al. All-Inside Repair for a Root Tear of the Medial Meniscus Using a Suture Anchor. *Am J Sports Med.* 2012

# Transtibial Meniscal Root Repairs

# Transtibial (tunnel) Meniscal Root Repairs

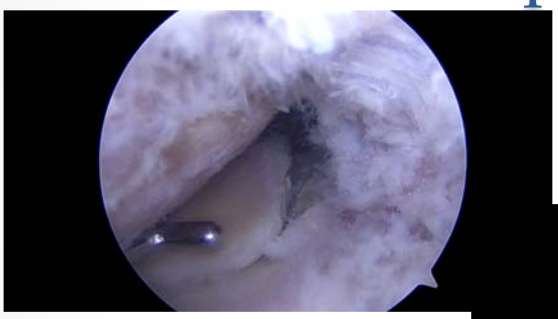

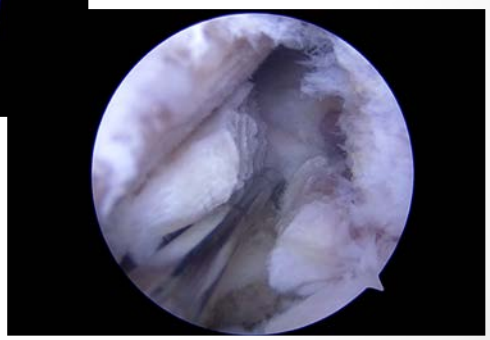

# Transtibial Meniscal Root Repairs

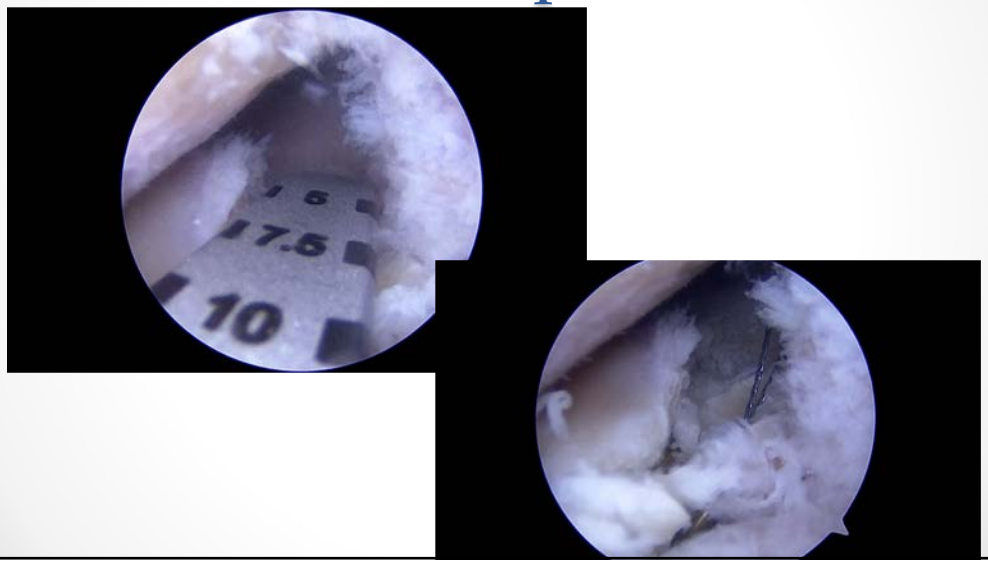


# Transtibial Meniscal Root Repairs

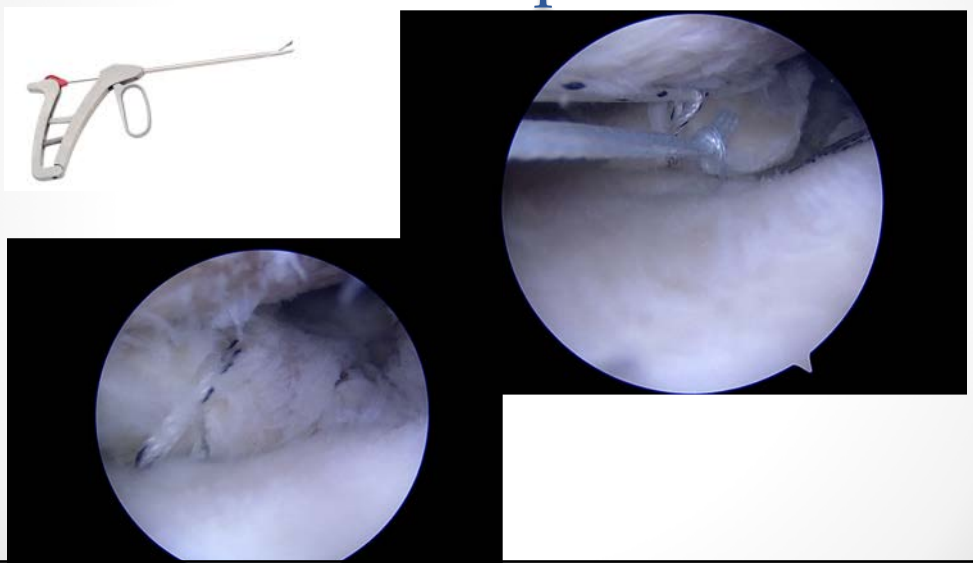

# Transtibial Meniscal Root Repairs

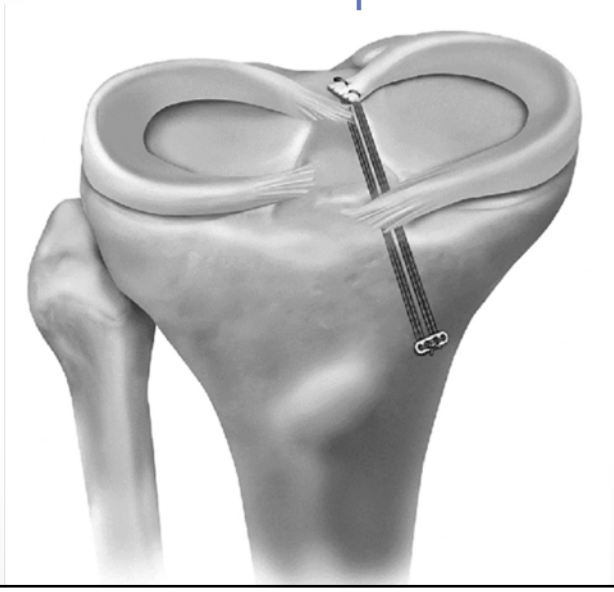

## Posterior Meniscal Root Repairs – Outcomes of an anatomic Trantibial Pull-Out Technique

- LaPrade RF. et al. AJSM 2016
- 50 transtibial root repairs
- Mean age 38.3
- All improved functional / pain scores, regardless of age or meniscal laterality. (Age <50 = >50)

- LaPrade RF, et al. Posterior Meniscal Root Repairs – Outcomes of an anatomic Trantibial Pull-Out Technique. AJSM 2016.

# Biologic Augmentation

- Mechanical stimulation: Fox JM, et al.[1] 1993. **Trephination** - 27/30 pts. (90%) reported good to excellent results.
- Marrow venting: Dean CS, et al.[2] 2017. **Intercondylar notch drilling** w/ repair vs ACL recon w/ repair. No difference in meniscus repair failure at 2 years.
- Fibrin clots: Jang SH, et al.[3] 201. **Inside-out repair with fibrin clot** - success rate of 95% (39/41) on second look arthroscopy at mean 8.3 months.

-Ra, et al.[4] 2013. Inside-out repair of radial tears with fibrin clot 91.7% (11/12) complete healing on MRI.

1. Fox JM, et al. Trephination of incomplete meniscal tears. *Arthroscopy* 1993. 9(4):451-455.
2. Dean CS, et al. Outcomes after biologically augmented isolated meniscal repair with marrow venting are comparable with those after meniscal repair with concomitant anterior cruciate ligament reconstruction. *Am J Sports Med*. 2017. May;45(6):1341-8.
3. Jang SH, et al. Fibrin clot delivery system for meniscal repair. *Knee Surg Relat Res*. 2011 Sep;23(3)180-3.
4. Ra HJ, et al. Arthroscopic inside-out repair of complete radial tears of the meniscus with a fibrin clot. Knee Surg Sports Traumatol Arthrosc. 2013 Sep;21(9):2126-30.

# Biologic Augmentation

- PRP injections: **Limited high level human studies.** Pujol N, et al.[1] 2015 (level III case series)

-- Improved pain / function 24 mos. w/ PRP injected at repair site.
--No difference in reoperation rate between repairs alone and repairs with PRP.

- Stem cell-based therapies: **Limited high level human studies**.

Vangsness TC, et al.[2] 2014. (Level 1- DB/R/C) Intra-articular allogenic adult hMSC's injected after partial medial meniscectomy:

-- 24% had significant (>15% volume) increased meniscal volume on MRI at 1 year, compared to 0% of control.
-- Safe, no ectopic formation
-- Improved VAS scores compared to control.

1. Pujol N, et al. Platelet-rich plasma for open meniscal repair in young patients: any benefit? *Knee Surg Sports Traumat Arthrosc*. 2015 Jan;23(1)51-8.
2. Vangsness TC, et al. Adult human mesnchymal stem cells delivered via intra-articular injection to the knee following partial medial meniscectomy: a randomized, double-blind, controlled study. *J Bone Joint Surg Am*. 2014 Jan 15;96(2):90-8

# Biologics Bottom Line

"Overall, the use of biologics in ACL and meniscal surgery has demonstrated some clinical benefit and remains promising, but the existing data should be considered preliminary due to a lack of definitive evidence"

- Hutchinson, *J Knee Surg* 2015

Hutchinson, I.D., Rodeo, S.A., Perrone, G.S., Murray, M.M., 2015. Can Platelet-Rich Plasma Enhance Anterior Cruciate Ligament and Meniscal Repair? *J Knee Surg* 2015; 28(01): 019-028.

# Summary

- Understanding meniscal anatomy / vascularity and tear patterns will assist in decision making process.
- Repair vs excision – repair when reliable healing is possible.
- Acute injury > chronic / degenerative
- Fixation method is dependent on type of tear
- Root tears require special attention.
- Biologics probably have a role – more to follow.


# Contact Information

Joshua A. Tuck, D.O., M.S., FAOAO

Orthopedic Surgeon,
Specializing in Orthopedic Sports Medicine and Arthroscopy

**LECOM Sports & Orthopedic Medicine**
5401 Peach Street, Suite 3300, Erie, PA 16509
Ph: 814.868.7840 • Fax: 814.868.2139
www.maerie.org, jtuck@mch1.org