

Vulvar Pain: A Common and Under-Recognized Pain Disorder in Women

Presenter: Dr. Chevelta A. Smith
August 2016

Case Presentation 1

- A 65 year old G3P2 presents to the office with concerns of concerns of constant bacterial infections for the past few months. Patient also states about 20 years ago she has a vaginal infection from chemicals working in a grape field. Patient uses “a cream” to help with the itching
- Regarding the itching, patient states, “I’ve had it all my life” She has been using a compound and it has been helping. She chronic “soreness,” however, she states that she can never see anything when she looks with a mirror. She can “feel it” with touching. States, “it feels swollen.” Further history reveals that it burns with “showers and walking.”
- Patient is sexually active. However, she states that she has not been able to have intercourse due to the chronic itching and soreness. She is married.
- Patient reports that she has not had a history of sexually transmitted diseases.

Case Presentation 1

- **ROS** - Denies fever, chills, nausea, and vomiting. +clear, vaginal discharge with no odor
- **PMH** - HTN, arthritis, back pain, migraines, anxiety, depression, hemorrhoids, GERD, asthma, “kidney problems”
- **FMH** - noncontributory
- **PSH** - Operative procedure on knee, Arthroscopy of knee joint
Sacrocolpopexy, Cystoscopy and Suburethral Sling 5/12/09
TAH/BSO 06/21/1989
- **ALL** - NKDA
- **Soc** - negative for ETOH, Tob use, or drugs. Married

Case Presentation 1

- **VSS**
- **External genitalia:** No erythema, lesions, or masses.
- **Clitoris:** normal sized, without lesions, and pain on palpation.
- **Labia:** No erythema, lesions, or masses. There is no discharge.
- **Cervix:** absent
- **Vagina:** Vaginal mucosa is pink. No vaginal discharge noted. No erythema. No gross lesions appreciated. No obvious atrophic changes noted. Scarring noted at vaginal apex. Cuff intact. Vaginal palpation demonstrates tenderness to palpate the anterior 6-7/10. No other tenderness to palpate posterior and lateral walls.

Cotton Swab Test

Vulva

- No **inner thigh** pain to palpate bilaterally
- **Mons Pubis** - non tender to palpate the fattier portion. However lower portion of the mons pubis, just superior to the left labia majora 2/10 pain with palpation
- **Right labia majora** - 7/10 (mid aspect)
- **Left labia majora** - 2/10 (mid aspect)
- **Clitoris** - 0/10

Vestibule

- 12 o'clock - 8/10
- 1 o'clock - 0/10
- 2 o'clock - 8/10
- 3 o'clock - 10/10
- 4 o'clock - 10/10
- 5 o'clock - 10/10
- 6 o'clock - 8/10
- 7 o'clock - 10/10
- 8 o'clock - 10/10
- 9 o'clock - 8/10
- 10 o'clock - 10/10
- 11 o'clock - 10/10

Care Plan - Case Presentation 1

- Aptima collected and sent to evaluate vaginal discharge. Discussed with patient that the discharge can be infectious or postmenopausal symptoms.
- Discussed with patient high suspicion for Vulvodynia, chronic vulvar pain. Will await vaginal cultures to rule out other etiology of pain.
- Discussed a trial of Elavil 25 mg PO QD. Will titrate up to a dose that brings relief or significant improvement.
- SE of Elavil discussed with patient to include but not limited to: dry mouth, heart arrhythmia, diarrhea, nausea, vomiting. Patient to watch for signs.

Care Plan - Case Presentation 1

- Also discussed with patient that albuterol and Elavil may have negative interaction. Pt states that she is not taking Albuterol at present. Usually needs it in the winter for her asthma. Patient instructed to discuss the interaction between albuterola and Elavil with pharmacist when she goes to pick up medication. She agrees to do so.
- Patient to follow up in 1-2 weeks for results and reevaluation.
- Prescription sent electronically and instructions regarding how to take medication was discussed with patient in detail.
- Side effects of medication(s) reviewed with patient.

Follow up 6/20/16

- Patient reports complete resolve of vaginal discharge
- Still some itching and soreness
- Vaginal cultures negative
- Increased Elavil by 10mg to 35mg
- Follow up in 1 week and repeat cotton test
- Patient happy with plan.

Follow up 6/28/16

- Patient states no complaints. No further vulvar itching. Patient states she did "a test" to see if the Elavil was really helping. She stopped for two days and noticed symptoms return, specifically the vaginal discharge.
- Discussed with patient vaginal discharge as a symptom of PM status and also can be a manifestation of a dairy allergy in women. Patient states she eats lots of cheese. Encouraged a 4 week trial in which she does not eat dairy and monitor vaginal discharge. She will consider doing it later. Not now.
- Will continue 35mg Elavil daily. Patient going out of town to Puerto Rico. Will follow up and repeat cotton swab test when she returns.
- Medication refilled. No side effects reported. Tolerating medication well.

Case Presentation 2

- 3/31/16
- A 9 year old G0 presents to the office with her mother and grandmother for evaluation of intermittent yellow vaginal discharge. Mom states (and patient confirms) "that patient has been complaining "that it burns on the outside of the vaginal area." Patient also complains that at times it may also smell. She reports that these symptoms have been going on for about 5 months.
- Further history reveals that it burns with "showers and walking."
- Mom has been using Nystatin cream "down there" at least twice weekly despite negative cultures. Patient states that it helps some, however, mom states that the vulva becomes very red and swollen.

Case Presentation 2 cont'd

- PMH - negative
- FMH - noncontributory
- PSH - negative
- ALL - NKDA
- Soc - negative for ETOH, Tob use, or drugs. Patient and family denies sexual abuse, molestation, etc. from family, friends of adults in the home, or parents. Patient also denies that anyone at school or her friends have ever "hurt her or touched her down there." She denies putting foreign objects in her vaginal are.
- ROS - Vaginal discharge. Denies vaginal itching, pelvic pain

Case Presentation 2 cont'd

- Ht - 4'6" Wt - 88lbs BMI - 21.2 (overweight)
- PE - AO x 3, Well groomed and well nourished
- Respiratory - no rales, wheezes, rhonchi
- Heart - RRR without murmur appreciated
- GI - abdomen soft, nontender, no guarding or rigidity. BS normal, no palpable masses

Case Presentation 2 cont'd

• Genitourinary -

- **External genitalia** without erythema, lesions, or masses. No evidence of lichen sclerosus, Lichen simplex chronicus, or lichen planus. Vulva around introitus appears erythematous (R>L). No other gross lesions or abnormalities appreciated.
- Tanner stage I genitalia. Hymen appears intact.
- **Cotton Swab test:**
 - 8-9 o'clock demonstrated moderate-severe pain with patient jumping up table. Patient states intense burning felt with palpation. Patient declined further palpation.
- **Culture obtained.** No vaginal discharge or odor appreciated.
- **Patient's behavior appropriate** for exam.

Vulvodynia in children



Reed B, Cantor L. Vulvodynia in Preadolescent Girls. *Journal of Lower Genital Tract Disease* 2008; 12 (4): 257-261.

Camille C, Yeh J. Vulvodynia in Adolescence: Childhood Vulvar Pain Syndromes. *Journal of Pediatric Adolescent Gynecology* 24 (2011) 110-115.



Care Plan - Initial Visit 3/31/16

Discussed suspicion for Vulvodynia with Mom and MGM despite limited exam
Offered referral to PgH or Cleveland Clinic - Declined
Patient instructed to avoid use of harsh soaps, lotions, creams, etc in genital area
Sitz baths once daily and blot dry
May consider use of vaseline or aquaphor for barrier protection of the skin
Keep journal regarding pain and diet, and clothing worn
Brief research of vulvodynia in children initiated and its occurrence confirmed
Phone consultation with Dr. B. Chekka regarding use of Elavil in children.
Post visit call placed to mom to discuss findings
5mg pill daily started. (0.1mg/kg loading dose for 1-2 weeks), increase as needed

Follow up visit 4/11/16

Patient reports no further discharge or burning and that medicine has worked "great."

Mom reports patient has no longer been complaining about pain since starting the medication. Patient stated that she no longer has pain with walking or when wiping after urination. Additionally, there has been no further episodes of vulvar swelling.

Patient denied dry mouth or other symptoms of the medication

Follow up visit 4/11/16

Repeat GU exam demonstrated significant decrease in erythema surrounding the introitus, than previously noted.

No vaginal discharge or odor appreciated. External genitalia appears normal. No obvious areas of scarring noted.

Cotton swab test repeated: inner thighs, mons pubis, labia majora - no pain. 12 o'clock - intense pain, patient declined further testing.

Provoked Vulvodynia with significant improvement

Follow up visit 4/11/16

Elavil increased to 10mg

Articles on Vulvodynia in children given to mom.

Plan reviewed with mom and patient to continue Elavil for 6 months and discontinue based on studies.

Mom and patient happy with plan. Will reevaluate in a few weeks.

Follow up visit 5/16/16

Patient states she is feeling "good" and denies burning, discharge and itching

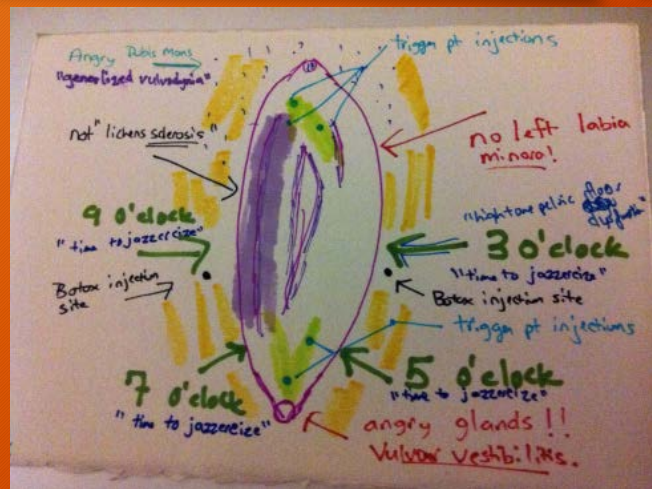Patient very happy with no complaints. Denies any pain at all.

Taking Elavil without complications or SE. States she has noticed more improvement with its increase to 10mg. States she has no problems washing genital area during bath time.

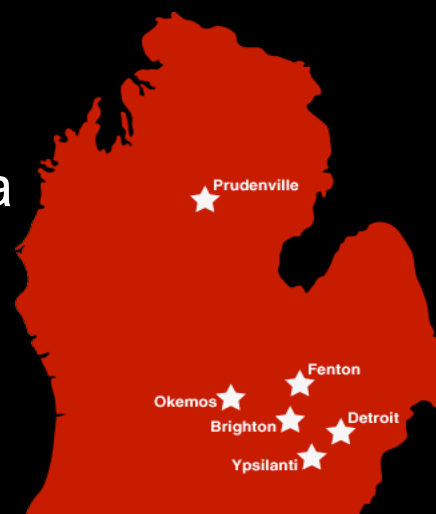Patient declined reevaluation with cotton swab testing. Will follow up in 3 months.

VULVODYNIA

CHRONIC VAGINA PAIN



8.3% of women have vulvodynia



Reed BD, Harlow SD, Sen A, Legocki LJ, Edwards RM, Arato N, Haefner HK. Prevalence and demographic characteristics of vulvodynia in a population-based sample. Am J Obstet Gynecol 2011.



Not Your Typical Complaint!



Itching

Stabbing

Stinging

Burning

Irritation

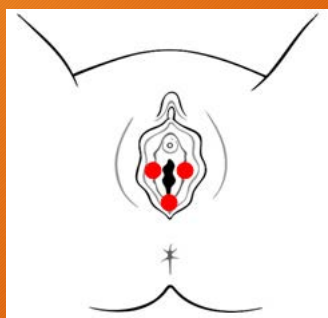Rawness

ISSVD DEFINITION OF VULVODYNIA

(International Society Study of Vulvovaginal Disease)

- Vulvar pain of at least 3 months' duration, without clear identifiable cause, which may have potential associated factors
- **Descriptors:**
 - Localized (e.g. vestibulodynia, clitorodynia) or Generalized or Mixed (localized and generalized)
 - Provoked (e.g. insertional, contact) or Spontaneous or Mixed (provoked and spontaneous)
 - Onset (primary or secondary)
 - Temporal pattern (intermittent, persistent, constant, immediate, delayed)
 - -----
 - *Women may have both a specific disorder (e.g. lichen sclerosus) and vulvodynia

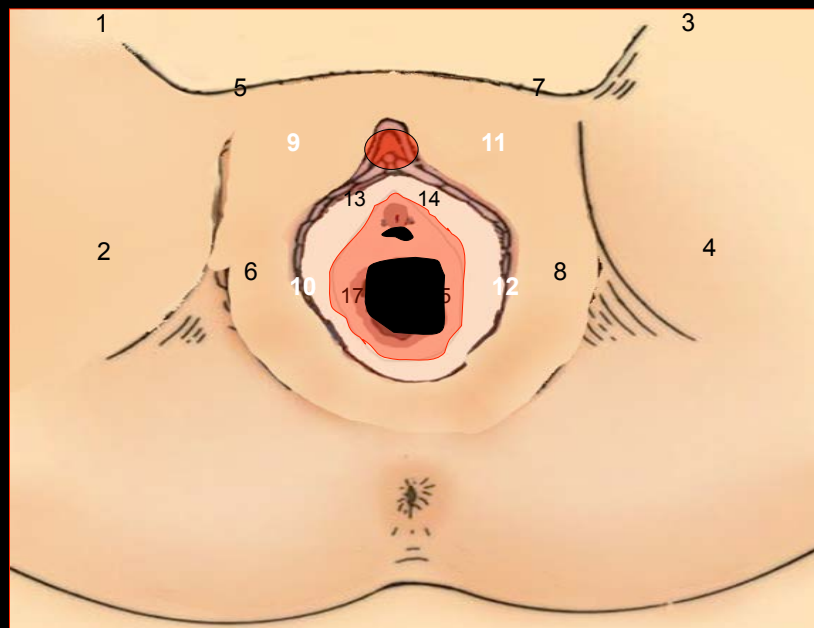
Localized Vulvodynia



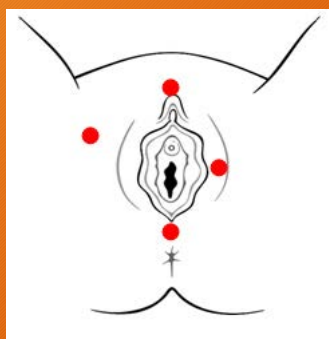
- Pain in one area of the vulva
 - Vestibulodynia - common
 - Clitorodynia - not as common, however it can very painful.
 - Hemivulvodynia
- Provoked, Unprovoked, Mixed
- Provoked Vestibulodynia is commonly experienced by women diagnosed with localized vulvodynia
 - Primary or Secondary

Photo from National Vulvodynia Website (nva.org)

Localized



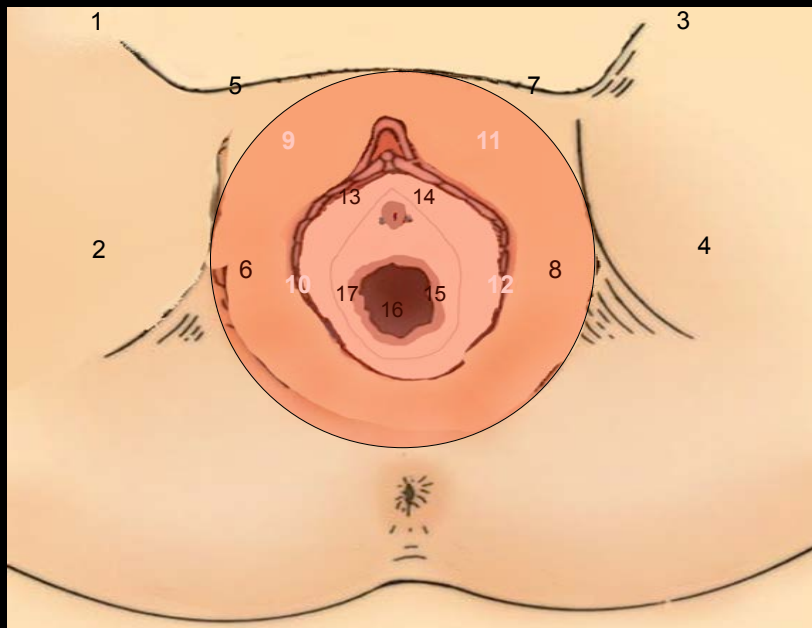
Generalized Vulvodynia



- Generalized Vulvodynia
 - Vulvar pain, usually constant however it can resolve for periods of time.
 - Pain occurs spontaneously
 - Pain manifestation may be in specific areas (i.e one labia, or near clitoris) or multiple areas (labia, vestibule, clitoris)
 - Pain may also manifest in other areas outside of the vulva (perineum, inner thighs)

Photo from National Vulvodynia Website (nva.org)

Generalized



Causes of Vulvodynia

- An injury to, or irritation of, the nerves that transmit pain from the vulva to the spinal cord
- An increase in the number and sensitivity of pain-sensing nerve fibers in the vulva
- Elevated levels of inflammatory substances in the vulva
- An abnormal response of different types of vulvar cells to environmental factors such as infection or trauma
- Genetic susceptibility to chronic vestibular inflammation, chronic widespread pain and/or inability to combat infection
- Pelvic floor muscle weakness, spasm or instability

nva.org

Vulvodynia Workup

Take a good history

Duration ?

Location?

Sensation?

Presentation?

Trauma?

Medications?

Physical Exam

Vulva

Vagina

Cotton swab test

? Biopsy

Laboratory workup

Cultures

No blood work

Diagnosis of Vulvodynia

Define disease

Von Frey filaments?

Cotton swab test


Vulvoscopy?

Duration of pain

Von Frey filaments



Von Frey filaments



Donders GG, Bellen G. Assessing severity of pain in women with focal provoked vulvodynia: are von Frey filaments suitable devices? *J Reprod Med* 2014;59:134-8.

Von Frey filaments are less suitable devices to assess severity of disease and response to treatment than are cotton swab 1 to 10 pain scores and clinical parameters like subjective pain (Visual Analogue Scale) and objective focal redness.

Diagnosis of Vulvodynia

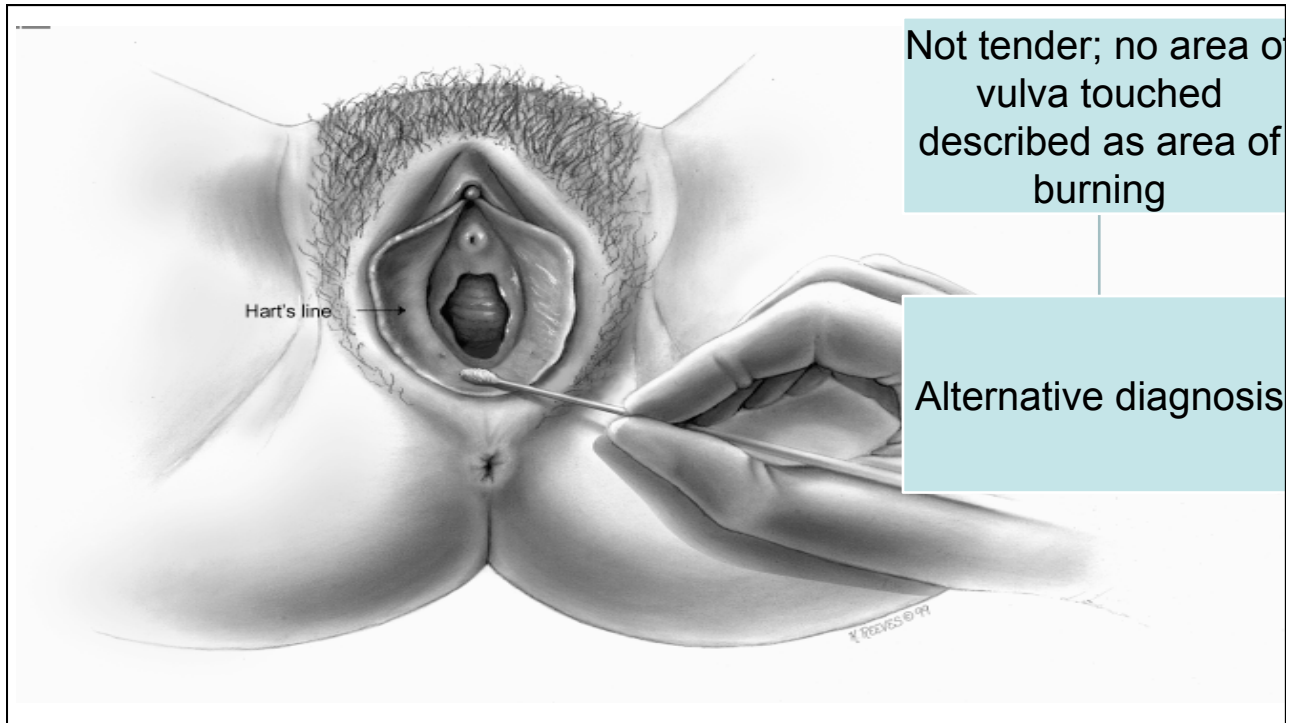
Define disease

Von Frey filaments?

Cotton swab test

Vulvoscopy?

Duration of pain



VULVODYNIA
A DIAGNOSIS OF EXCLUSION

COEXISTING PAIN SYNDROMES



- Fibromyalgia
- Interstitial Cystitis
- Irritable Bowel Syndrome

The Prevalence of Fibromyalgia by Tender Point Tenderness in Women With Localized Provoked Vestibulodynia

Women with PVD had a higher prevalence of FM by TPT than that which is reported in the general population (17.7% vs 2–6.4%), and a higher prevalence of fibromyalgia by tender points than would be expected by personal and family history (17.7% vs 8.4%).

Phillips N, Brown C, Bachmann GA, Foster D, Rawlinson L, Wan J.
Obstetrics & Gynecology 12016;27 Supplement 1:34S

Similarities Between Interstitial Cystitis/Bladder Pain Syndrome and Vulvodynia: Implications for Patient Management

- Intertwined from the perspectives of embryology, pathology and epidemiology
- Similar responses to therapies

Fariello and Moldwin 2015

Unprovoked Vestibular Burning in Late Estrogen-Deprived Menopause: A Case Series

Goetsch MF. JLGTD 2012; 16:442-446

- 7 menopausal women range 1-4 years of pain (1 patient on oral estradiol)
- 3 developed pain after aromatase inhibitor
- Utilized lidocaine, local estrogen to vestibule and physical therapy

Lack of Estrogen

- Seventy-one percent (15/21) of postmenopausal women reported vestibular dyspareunia related to a drop in estrogen either with menopause (13/21) or previously, postpartum (2/21). Eighty-six percent (18/21) of postmenopausal patients were using local or systemic estrogen but pain persisted.

Leclair, 2013

Treatment for Vulvodynia

Avoid Irritants

Tight pants
Thongs
Perfumed soaps or other scented products
Products with dyes and chemicals
Daily use of panty liners

Medications

Topical anesthetics

Tricyclic antidepressants

Gabapentin
Pregabalin
Venlafaxine
Duloxetine
Estrogen

Surgery/Other Treatment

Pelvic Floor Muscle Therapy
Nerve Blocks
Neurostimulation
Spinal Infusion Pump
Surgery (for PVD)
Alternative Medication
Referral

nva.org



The End!